



PATIENT

Monty Novak

SPECIES

Canine

BREED

Lhasa Apso

SEX

Neutered Male

AGE

10 Years

WEIGHT

17 Pounds

PRESENTING CLINICAL SIGNS

History: Recent heart murmur and elevated liver values.

Abnormal PE/Chem/CBC/UA Results: ALT 774, Alk. Phos. 225, GGT 18, chol. 454. U/A: trace protein, WBC 4-10, squamous epithelia 4-10. Distemper - IGG (positive). Parvovirus IGG (positive).

ULTRASONOGRAPHIC EXAMINATION OF THE HEART & ABDOMEN

CANINE CARDIAC PARAMETERS	MR VMAX (m/s)	TR VMAX (m/s)	LA/AO (Boon method)	LA/AO (Heart Base; Swe)	FS (%)	EF (%)	EPSS (cm)
NORMAL PARAMETER	4.5-5.5	<2.7	1.3	<1.3	28-40	40-100	<0.6
PATIENT	6.0	1.5	1.2	1.4	34	64	0.1
CANINE CARDIAC PARAMETERS	HR (BPM)	AV VMAX (m/s)	PV MAX (m/s)	BODY WEIGHT (kg)	LA 2D short axis Base view (cm)	LVIDd Avg; 2D and m-mode short axis (cm)	LVIDs Avg; 2D and m-mode short axis (cm)
NORMAL PARAMETER	50-100	0.7-1.7	0.7-1.6				
PATIENT	88	1.07	.99	--	2.85	2.73	--

INTERPRETED BY

Eric Lindquist, DMV
DABVP, Cert. IVUSS

IMAGING PERFORMED BY

Kely Vazquez

HOSPITAL NAME

Marsh AH

REFERRING VET

Dr. Milwicki

INVOICE

16432

DATE

7/1/22

Cardiac Presentation

The echocardiogram in this patient demonstrated normal **left atrial** size based on 3 different LA measurement methods. Chamber volumes and echogenicity were normal. The cranial and caudal **mitral** valve leaflets presented vegetative thickening consistent with endocardiosis. Doppler indicated measurable insufficiency. The **left ventricle** presented thicknesses with linear contour and was not dilated nor restricted. The **myocardium** presented normal echogenicity without subjective evidence of significant fibrotic or ischemic disease. **Contractility** of the ventricular walls was adequate and in normal range for this patient evidenced by the fractional shortening measurement and subjective evaluation of the different regions of the myocardium. The **left ventricular outflow** tract demonstrated normal laminar flow and subjective structural integrity. The **right atrium** and auricle revealed normal size, structure and content. No evidence of masses was noted or chamber overload. **Tricuspid** valvular assessment demonstrated adequate linear morphology. Minor tricuspid insufficiency noted. The **right ventricle** was of normal size (1/3 diameter of LV), chordae structure, myocardial echogenicity and thickness. **Pulmonic** tract assessment revealed normal valve structure, laminar flow, and diameter (approx. 1:1 pa/ao ratio). No visible **pericardial** or free pleura fluid was noted. No echographically detectable evidence of infiltrative disease was visible. The cranial **mediastinum and pericardial regions** were free of masses in the visible window.

Urinary System



PATIENT

Monty Novak

The **urinary bladder**, trigone, and pelvic urethra presented normal thicknesses and normal tone. The ureters were not visible which is normal. No uroliths or sediment were visualized and anechoic urine was present. No evidence of inflammatory or neoplastic changes were noted. Ureteral papillae were normal.

SPECIES

Canine

The **kidneys** revealed largely normal size and structure, corticomedullary definition and ratio (cortex 1/3 of medulla) were essentially maintained with some mild age-related loss of curvilinear patterns regarding the capsule and C/M junction. The cortices presented largely uniform texture with some increased echogenicity expected for his age patient. Medullary structure differed distinctly from that of the cortex and no evidence of pelvic dilation was present. The right kidney measured 3.85 cm. The left kidney measured 3.7 cm.

BREED

Lhasa Apso

Adrenal Glands

SEX

Neutered Male

The **left adrenal gland** was slightly enlarged at the cranial pole, measuring 0.8 cm at the cranial pole and 0.49 cm at the caudal pole x 1.79 cm in length.

The region of the **right adrenal gland** revealed no evident pathology.

AGE

10 Years

Spleen

WEIGHT

17 Pounds

The **spleen** presented a smooth homogeneous parenchyma hyperechoic to liver and renal cortical parenchyma. The capsule was smooth without noticeable expansion or deviation from within the spleen or adjacent pathology. The splenic vasculature demonstrated normal volume without signs of congestion or thrombosis. No sonographic evidence of acute or chronic inflammatory, neoplastic, or infarctual changes were noted.

INTERPRETED BY

Eric Lindquist, DMV
DABVP, Cert. IVUSS

Liver

The **liver** images submitted revealed subjectively normal liver size, contour, and structure. Parenchymal echogenicity was naturally coarse and hypoechoic to the spleen. Vascular and biliary tracts were of normal volume with no evidence of congestion. The gallbladder presented acceptably thin walls with primarily anechoic content. The cystic and common bile ducts were normal. No pathological hepatic lymphadenopathy was evident. No overt structural evidence of inflammatory, infiltrative or regenerative pathology was evident.

IMAGING PERFORMED BY

Kely Vazquez

Gastrointestinal

HOSPITAL NAME

Marsh AH

The stomach revealed a minor amount of luminal fluid with echogenic mucosal hypertrophy and minor remodeling consistent with low grade gastritis.

Pancreas

REFERRING VET

Dr. Milwicki

The base and limbs of the **pancreas** were observed to be largely isoechoic to surrounding omental fat. Pancreatic duct and capsular contour were acceptably normal and parenchyma respected normal curvilinear patterns. No overt evidence of active inflammatory or neoplastic disease was noted.

INVOICE

16432

ULTRASONOGRAPHIC FINDINGS

- Stage B-1 valvular disease
- Minor tricuspid insufficiency
- Slightly enlarged left adrenal gland
- Low-grade gastritis pattern with age-related abdominal changes otherwise

DATE

7/1/22



PATIENT

Monty Novak

SPECIES

Canine

BREED

Lhasa Apso

SEX

Neutered Male

AGE

10 Years

WEIGHT

17 Pounds

INTERPRETED BY

Eric Lindquist, DMV
DABVP, Cert. IVUSS

IMAGING PERFORMED BY

Kely Vazquez

HOSPITAL NAME

Marsh AH

REFERRING VET

Dr. Milwicki

INVOICE

16432

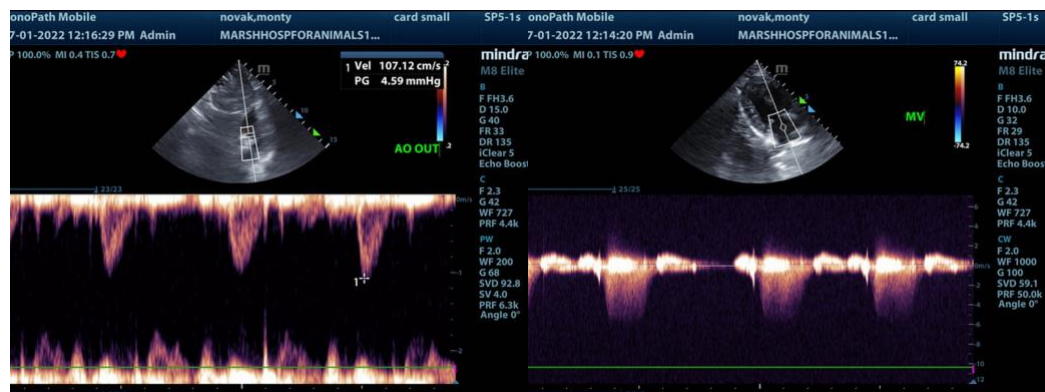
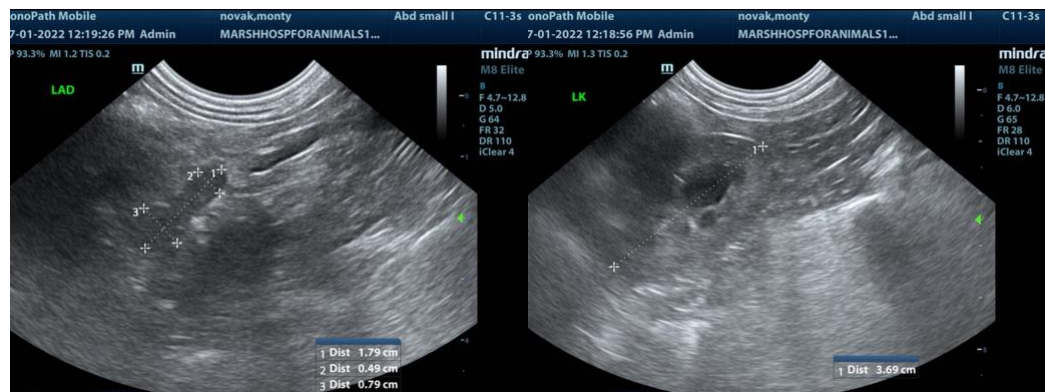
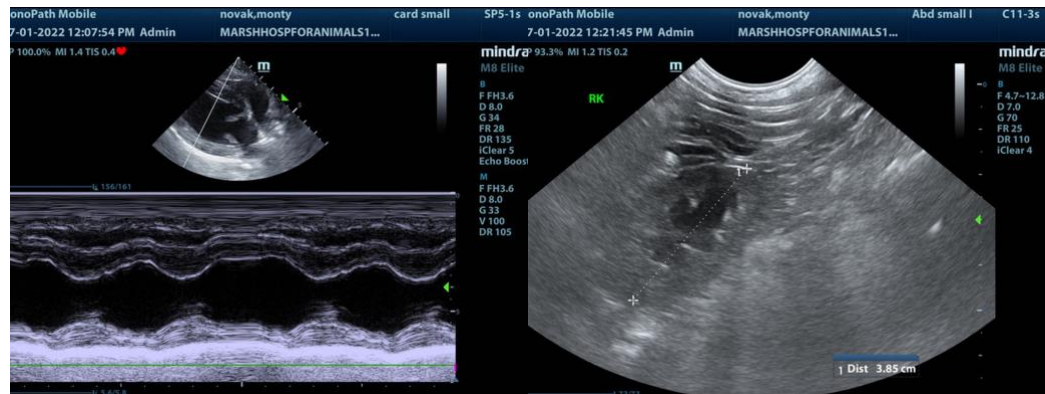
DATE

7/1/22

INTERPRETATION OF THE FINDINGS & FURTHER RECOMMENDATIONS

The heart is stable without clinical disease. No overt contraindication for anesthesia of brief to moderate duration. I suggest Torbutrol premed, Propofol induction, Isoflor maintenance or similar protocol if anesthesia is desired. Blood pressure recommended if not already performed and target white coat negative systolic pressure of < 160 mmHg. If higher than this ACE-inhibitor is suggested to reach this level. Recheck echocardiogram is recommended in 6 months, earlier if murmur grade increases or clinical signs initiate. No treatment recommended.

Given the pyuria, full urinary work up with culture indicated. Benign abdomen otherwise. FNA of the liver could be considered for further definition yet structurally appears benign.





PATIENT

Monty Novak

SPECIES

Canine

BREED

Lhasa Apso

SEX

Neutered Male

AGE

10 Years

WEIGHT

17 Pounds

INTERPRETED BY

Eric Lindquist, DMV
DABVP, Cert. IVUSS

IMAGING PERFORMED BY

Kely Vazquez

HOSPITAL NAME

Marsh AH

REFERRING VET

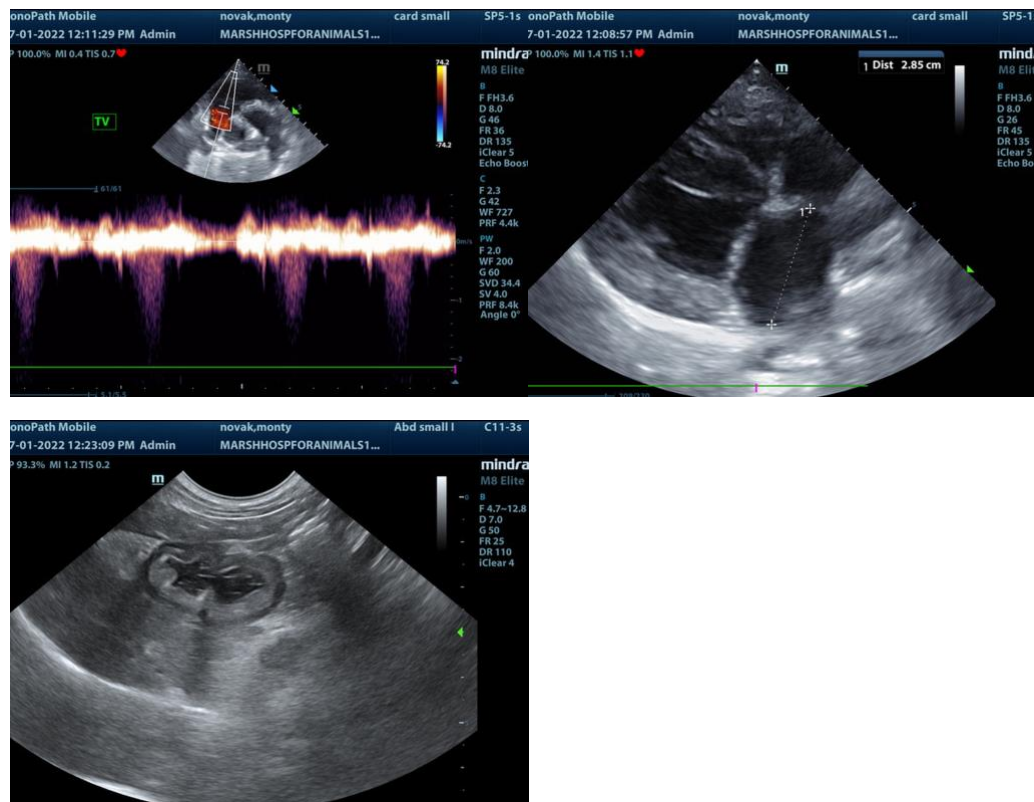
Dr. Milwicki

INVOICE

16432

DATE

7/1/22



The information and recommendations provided are based on the images presented by the referring veterinarian. No evaluation can be communicated regarding pathology that was not visible in the image/video clips provided.

Thank you for this referral. If the clinical or image interpretation does not parallel your findings or if I can be of any further assistance please contact me.

Eric Lindquist, DMV, DABVP, Cert. IVUSS, CEO of SonoPath.com
info@SonoPath.com